



PATIENT

Bradley Newman

PRESENTING CLINICAL SIGNS

History: Elevated ProBNP was noted. No heart murmur, coughing or arrhythmia noted. Thoracic mass (suspected thymoma) diagnosed via radiographs and CT scan in May 2022. Assess prior to anesthesia.

SPECIES

Canine

BREED

Shih Tzu

SEX

Female Spayed

ECHOCARDIOGRAM FINDINGS

2D, m-mode, color flow and doppler imaging is available. Mild diffuse thickening of mitral valve leaflets with no prolapse into the left atrial lumen. Trace/mild eccentric mitral regurgitation with no left atrial dilation. Normal MR velocity. Normal LV diameter with adequate myocardial function. The tricuspid valve appears normal with trace tricuspid regurgitation. Normal velocity. Normal right atrial and ventricular diameter and morphology indicating no overt evidence of pulmonary arterial hypertension. The pulmonic and aortic valves are normal in morphology and mobility. Normal pulmonic and aortic outflow velocities with laminar flow. No obvious aortic or pulmonic insufficiency. No pericardial or pleural effusion noted. No obvious cardiac masses. A large thoracic mass apparent throughout the study.

CARDIAC CHART

AGE

15.2 years

WEIGHT

8.3lbs

INTERPRETED BY

Maggie Machen Lamy,
DVM, DACVIM
(Cardiology)

IMAGING PERFORMED BY

Kim Liedberg

HOSPITAL NAME

SVS Imaging WI

REFERRING VET

Dr. Haynes

INVOICE

25833

DATE

8/17/22

CANINE CARDIAC PARAMETERS	MR VMAX (m/s)	TR VMAX (m/s)	LA/AO (Boon method)	LA/AO (Heart Base; Swe)	FS (%)	EF (%)	EPSS (cm)
NORMAL PARAMETER	4.5-5.5	<2.7	1.3	<1.6	28-40	40-100	<0.6
PATIENT	4.9	2.0	1.4	1.2	40	76	0.3
CANINE CARDIAC PARAMETERS	HR (BPM)	AV VMAX (m/s)	PV MAX (m/s)	BODY WEIGHT (kg)	LA 2D short axis Base view (cm)	LVIDd Avg: 2D and m-mode short axis (cm)	LVIDs Avg: 2D and m-mode short axis (cm)
NORMAL PARAMETER	50-100	0.7-1.7	0.7-1.6	BELOW	BELOW	BELOW	BELOW
PATIENT	140	1.1	1.1	3.8	1.4	2.0	1.2
*Normal chamber parameters expressed as a mean value (SD)				3	1.27 (5.3)	2.46 (2.46)	1.36 (5.5)
BODY WEIGHT DEPENDENT PARAMETERS				5	1.40 (4.5)	2.74 (5.2)	1.60 (4.7)
<i>*Note: All measurements based upon multi-modal images and methods. An average value is reported.</i>				10	1.50 (3.8)	3.27 (3.5)	2.06 (3.1)
				15	1.83 (2.0)	3.71 (2.4)	2.43 (2.1)
				20	2.02 (1.9)	4.14 (2.2)	2.80 (2.0)
				25	2.18 (2.4)	4.48 (2.9)	3.10 (2.5)
				30	2.33 (3.3)	4.83 (3.9)	3.39 (3.4)
				35	2.48 (4.3)	5.17 (5.0)	3.69 (4.5)
				40	2.62 (5.2)	5.48 (6.1)	3.96 (5.4)
				50	2.88 (7.1)	6.07 (8.3)	4.46 (7.4)

INTERPRETATION OF THE FINDINGS & FURTHER RECOMMENDATIONS

Chronic degenerative valve disease causing trace/mild mitral and tricuspid regurgitation. This is considered subclinical disease prior to onset of a murmur or chamber enlargement. Lack of significant left atrial enlargement indicates the current risk for complication is low. No concurrent issues such as systolic dysfunction or pulmonary hypertension are noted in this study. The previously noted thoracic mass is apparent and further evaluation may be warranted, depending on clinical picture.

IMAGING PERFORMED BY

svsmobileimaging.com 309 - 737 - 3070

**PATIENT**

Bradley Newman

These findings do not clearly explain an elevated BNP, although a potentially compressive thoracic mass may be contributing. Consider a baseline blood pressure to ensure no alternative cause for elevation is identified.

SPECIES

Canine

In a dog with no significant left atrial enlargement, no cardiac medications are clearly indicated. Assessment of progression in the future will help predict long term prognosis, which is highly variable at this stage (B1). Omega fatty acid supplementation and mild salt restriction may be of some long-term benefit. Monitor for development of a cough, labored breathing, exercise intolerance or collapse episodes.

BREED

Shih Tzu

No cardiac contraindication for general anesthesia.

SEX

Female Spayed

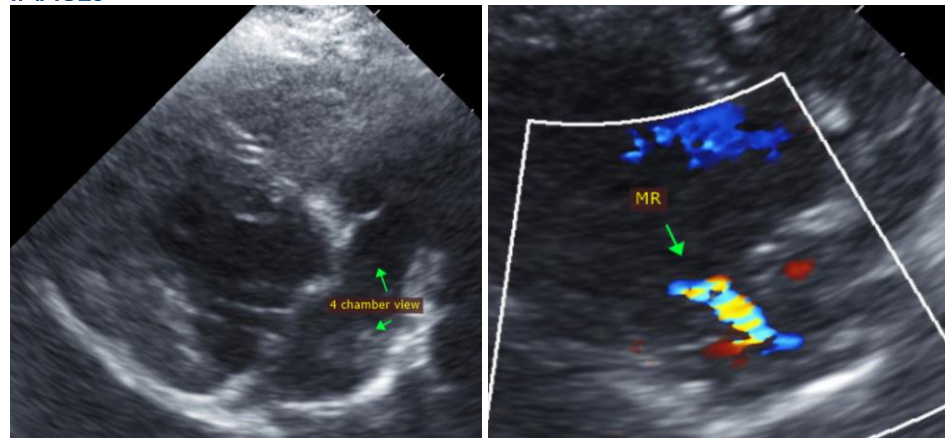
Recommend conservative monitoring with a recheck echocardiogram in 1 year, sooner if any development of clinical signs.

AGE

15.2 years

WEIGHT

8.3lbs

IMAGES**INTERPRETED BY**
 Maggie Machen Lamy,
 DVM, DACVIM
 (Cardiology)

The information and recommendations provided are based on the images presented by the referring veterinarian. No evaluation can be communicated regarding pathology that was not visible in the image/video clips provided.

IMAGING PERFORMED BY

Kim Liedberg

Thank you for this referral. If the clinical or image interpretation does not parallel your findings or if I can be of any further assistance, please contact me.

HOSPITAL NAME

SVS Imaging WI

 Maggie Machen Lamy, DVM
 Diplomat of the American College of Veterinary Internal Medicine (Cardiology)
 info@sonopath.com
REFERRING VET

Dr. Haynes

INVOICE

25833

DATE

8/17/22